

## Background

Non invasive tests are poorly developed in NAFLD. This could be partly due to the pathological description of certain lesions that is hampered by semi-quantitative scorings.

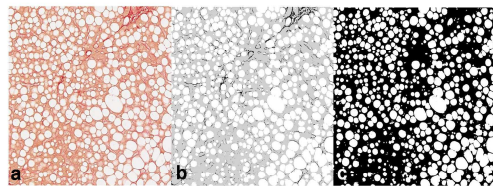
## Aims

Our aim was to develop an accurate non-invasive measurement of main liver lesions in NAFLD by blood tests based on a thorough pathological and morphometric analysis.

## Methods

- 225 patients with histologically proven NAFLD, clinical and biological data were included.
- Steatosis, NASH and fibrosis were graded according to CRN-NASH (Kleiner, *Hepatology* 2005) and Metavir systems.
- A fully automated in-house software of morphometry (Calès *et al*, *JG* 2010) measured the quantity (area: AOS, %) and the architecture (fractal dimension: FDS) of steatosis (figure 1), and the area (AOF) and the fractal dimension (FDF) of fibrosis.
- Blood tests were constructed by binary logistic regression for binary diagnosis (accuracy expressed as AUROC) and linear regression for quantitative diagnosis (accuracy expressed as  $aR^2$ ).
- Independent predictors were selected by logistic or multiple regression repeated in 1000 random bootstrap samples. When models were determined, a second bootstrap resampling was performed to measure optimism bias (Steyerberg *et al*. 2001).

## Measurement of area of steatosis



**Figure 1.** Measurement of area of steatosis. **Panel 1a:** capture of optical image of liver specimen with picosirius staining in a patient with NAFLD and grade 3 steatosis (x 20). **Panel 1b:** labeled digital image with 3 classes (steatosis vesicles in white, fibrosis tissue in black and others in grey). **Panel 1c:** binary digital image with steatosis vesicles in white used to calculate the area of steatosis.

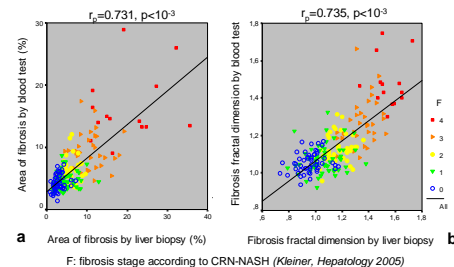
## Results

- They are summarized in **table 1** with raw diagnostic accuracy calculated on study population and *estimated* diagnostic accuracy after measurement of optimism bias.
- Correlation between area or fractal dimension of fibrosis measured on liver specimen and estimated by blood tests are presented in **figure 2**.

**Table 1: diagnostic accuracy of blood tests**

Diagnostic target	Variables	Score	Diagnostic accuracy	
			Raw	Estimated
<b>Significant fibrosis (AUROC):</b>				
Metavir F2	Weight, age, glycaemia, AST, ALT, ferritin, platelets	#1	0.941	0.927
CRN-NASH F2	Weight, glycaemia, AST, ALT, prothrombin index	#2	0.867	0.856
<b>Area of fibrosis (<math>R^2</math>)</b>				
	hyaluronic acid, glycaemia, AST, ALT, platelets, prothrombin index	#3	0.530	0.518
<b>Fractal dimension of fibrosis (<math>R^2</math>)</b>				
	hyaluronic acid, glycaemia, AST/ALT, weight, platelets	#4	0.529	0.517
<b>Significant steatosis (AUROC):</b>				
Relative AOS 23%	Triglycerides, AST/ALT, ferritin, score 2	#5	0.836	0.818
CRN-NASH Grade 21	BMI, glycaemia, triglycerides, ferritin, score 2	#6	0.835	0.813
<b>Area of steatosis (<math>R^2</math>)</b>				
	BMI, AST/ALT, triglycerides, score 2	#7	0.268	0.252
<b>Fractal dimension of steatosis (<math>R^2</math>)</b>				
	BMI, triglycerides, ferritin, score 2	#8	0.279	0.266
<b>NASH (AUROC)</b>				
	BMI, AST, ferritin	#9	0.846	0.836

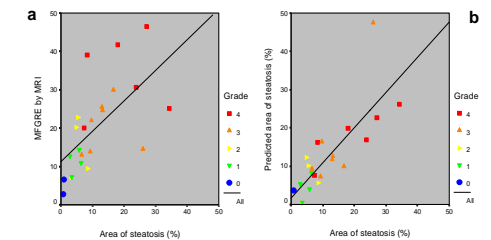
**Figure 2: Correlation between area or fractal dimension of fibrosis measured on liver specimen and estimated by blood tests**



## Discussion

- Accuracy for the diagnosis of significant fibrosis was excellent and unexpectedly better with Metavir F than with CRN-NASH F.
- The models for fibrosis quantification (AOF, FDF) had a satisfactory accuracy.
- Diagnosis of NASH was accurate.
- Unexpectedly, the diagnosis of steatosis was better with the CRN-NASH grade than with the objective measure of AOS.
- Finally, the models for steatosis quantification (AOS, FDS) had a poor accuracy, in contrast to MRI whose accuracy was however improved by its combination with blood variables (figure 3) (Cesbron *et al*, *EJGH* 2010).

**Figure 3: Correlation between area of steatosis and quantification of steatosis by MRI or MRI + blood variables**



**Figure 3.** Correlation between area of steatosis and (a) MFGRE sequence by MRI ( $r_s$ : 0.72,  $p < 10^{-3}$ ) or (b) predictive model (MFGRE sequence by MRI + ALAT + triglycerides) of area of steatosis ( $r_s$ : 0.845,  $p < 10^{-3}$ ) as a function of steatosis grade.

## Conclusions

- Blood tests have an excellent accuracy for the non invasive diagnosis of fibrosis (significant, area, fractal dimension) in patients with NAFLD.
- Accuracy of blood tests for the diagnosis of significant steatosis or NASH is very good.
- The non invasive quantification of steatosis by blood test remains poorly accurate, unless if it is combined with MRI.
- Finally, NAFLD liver lesions, such as steatosis (except for amount), NASH and fibrosis, can be diagnosed and quantified by blood tests with an excellent accuracy.